

Corneal wave-front aberrations following overnight orthokeratology

Antonio Calossi
 Certaldo, Florence, Italy

MATERIALS and METHODS

We treated 50 eyes of 25 myopic patients aged from 11 to 45 years, without any tear, corneal, ocular and/or systemic disease at the baseline time and without any previous ocular surgery. The baseline refractive error was from -1.00 to -6.00 D spherical equivalent, WTR astigmatism up to 1.50 D and ATR astigmatism up to 1.00 D.

Procedures: After the baseline examinations, we calculated and fitted the lenses. The fitting of the lenses was based on a trial lens set to assess the first behavior of the lens on the eye, then the geometric parameters of the lens were optimized through a custom software (fig.2). The lenses were adjusted to achieve optimal fluorescein pattern (fig.1), centration and dynamic behavior. For all the patients an overnight wear was scheduled. After dispensing, all the subjects wore the same pair of lenses during the whole study. The lenses were in siloxy-fluoro-methacrylate Dk 100 gas-permeable material (Boston XO, hexafocon-A).

Follow-up: Subjective rating, UCVA, BCVA, manifest refraction, corneal topography, and corneal wave-front analysis (EyeTop CSO, Florence, Italy) were collected during 3 month follow-up. The subjective quality of vision (QVS) was checked through a questionnaire. After overnight wear, the follow-up controls were performed in the morning and repeated in the evening after 1 night, 1 week, 2 weeks, 1 month, and 3 months. In the morning the lens in situ was inspected and then, after lens removal, all the examinations of the baseline time were repeated. These examinations were repeated in the evening of the same day.

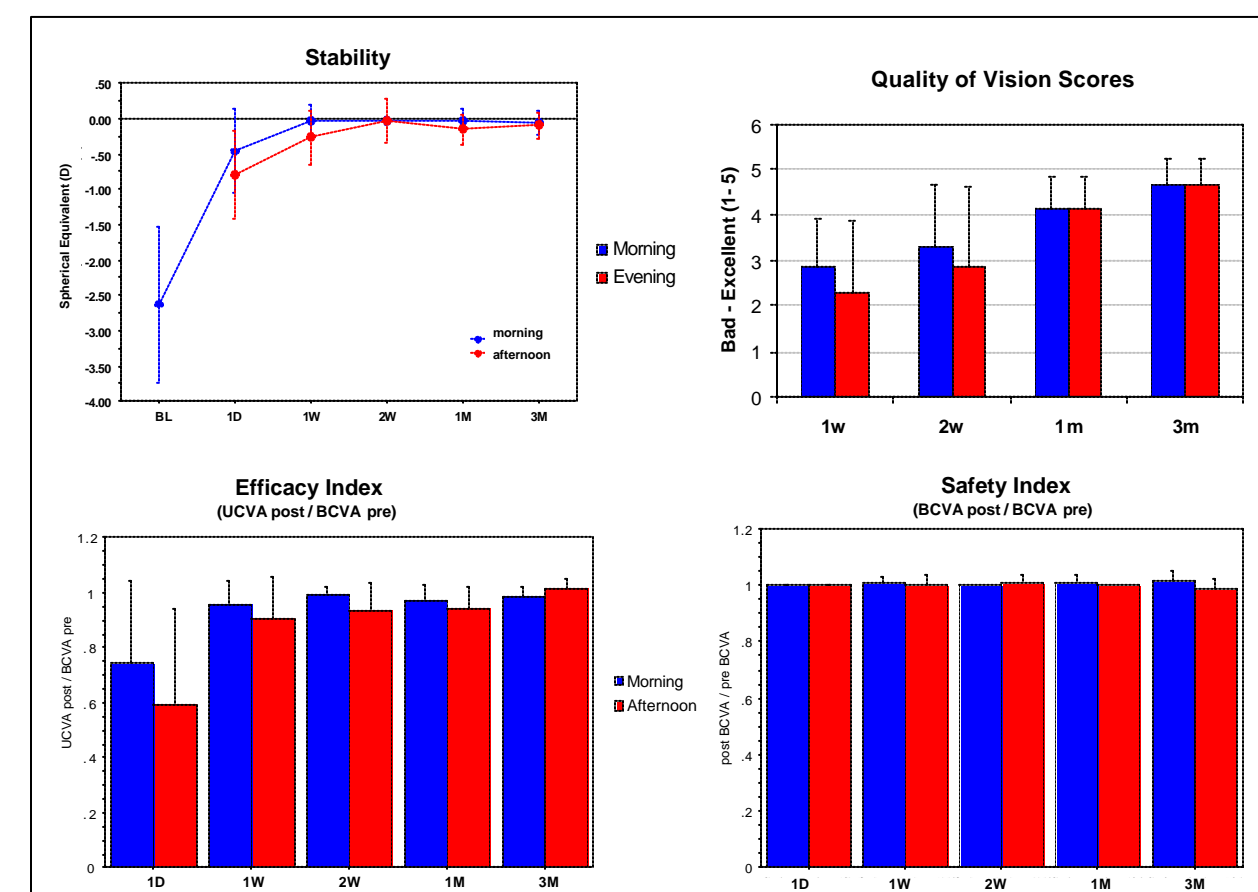


Fig.4 - Refractive and visual outcomes

RESULTS

The cornea responded rapidly with significant (Student *t* test: $p < 0.05$) central corneal flattening and improvement in visual acuity after the first night of lens wear; the corneal shape changed from prolate to oblate asphericity after 1 night of wear. By the end of 1 week, all corneal and visual changes had reached a maximal level and remained fairly stable during the day (fig.4,6). These changes were sustained at 2 weeks, 1 month and 3 months. The efficacy index (UCVA post / BCVA pre) after 1 night was 70% in the morning, and 60% in the evening with large SD; after 1 week it improved to 90% with smaller regression and small SD; after 2 weeks we had a little further improvement and stabilization. For all the period of the study the safety index (BCVA post / BCVA pre) was 1, that means no lost of BCVA lines.

The graphs in figure 5 show the changes in corneal wave-front aberrations. During the first week, there was a significant increase of corneal spherical aberration ($p < 0.05$) due to post-treatment oblate shape of the cornea. The spherical aberration was correlated with the amount of treated myopia and with pupil diameter, while coma aberration was correlated with the displacement of the pupil as regards the geometric center of the cornea and the center of the treatment (fig.3). Subjective ratings continued to improve after objective measures stabilized at 1 week (fig.4 QVS). Biomicroscopy showed no corneal infiltrates or ulcers; there were some observations of CCLRU grade 1 fluorescein staining of the cornea, and imprinting in the morning that disappeared in the evening; no other significant

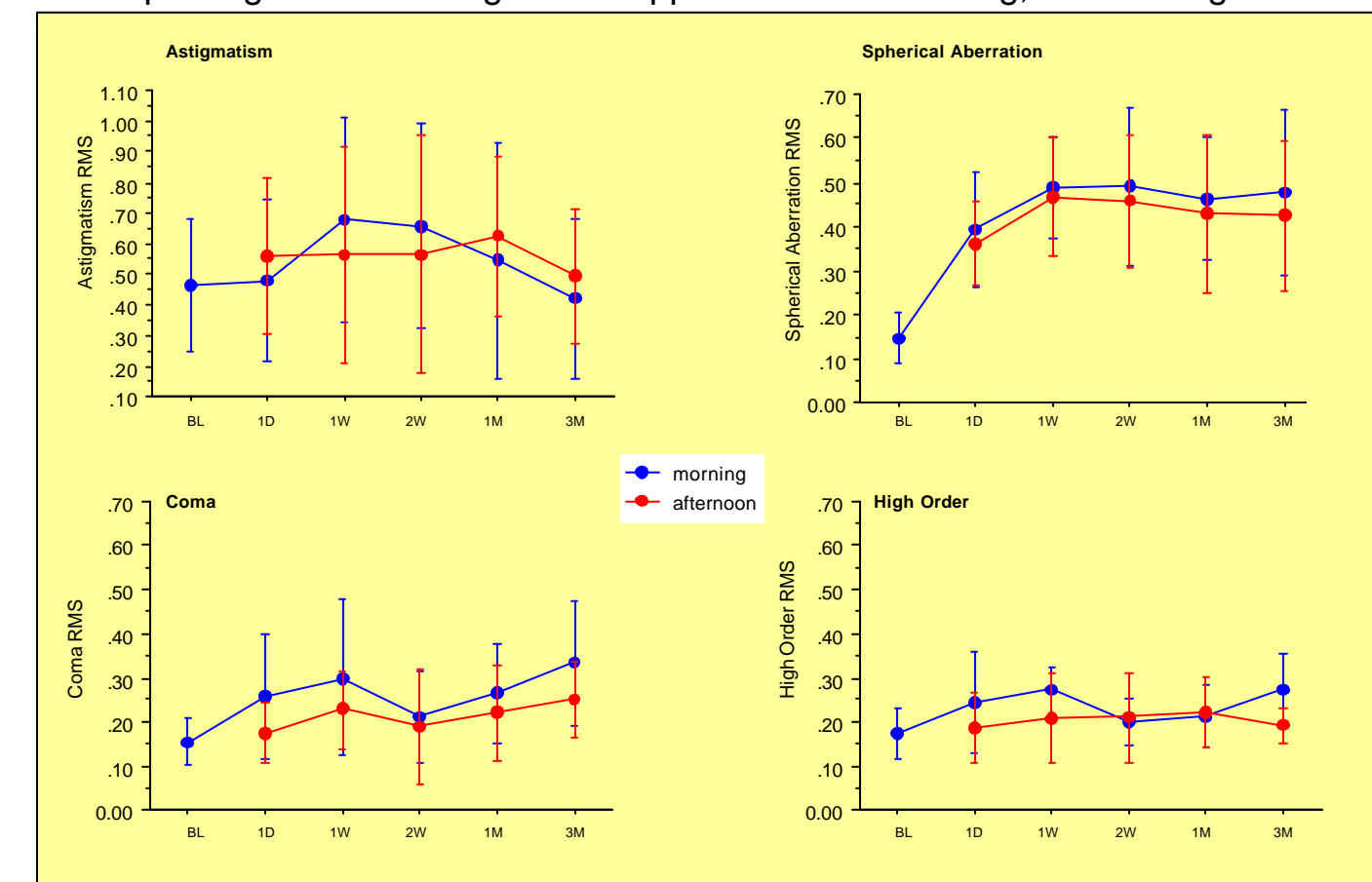


Fig.5 - Primary corneal wave-front aberrations

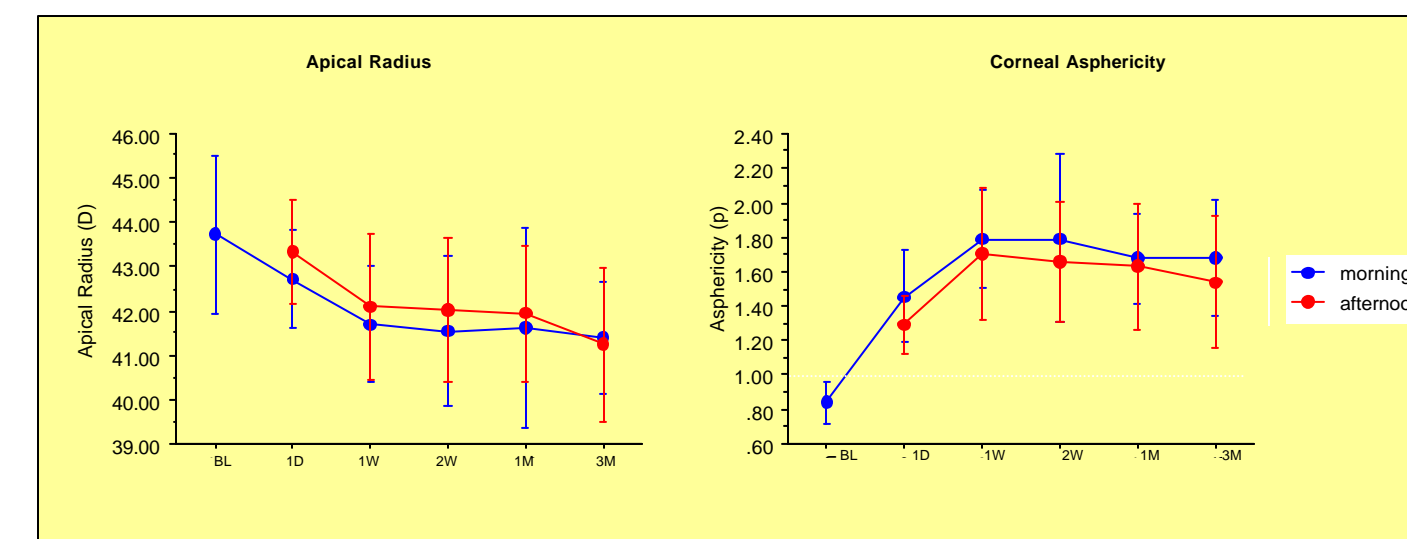


Fig.6 - Corneal topography: apical radius and shape factor (p)

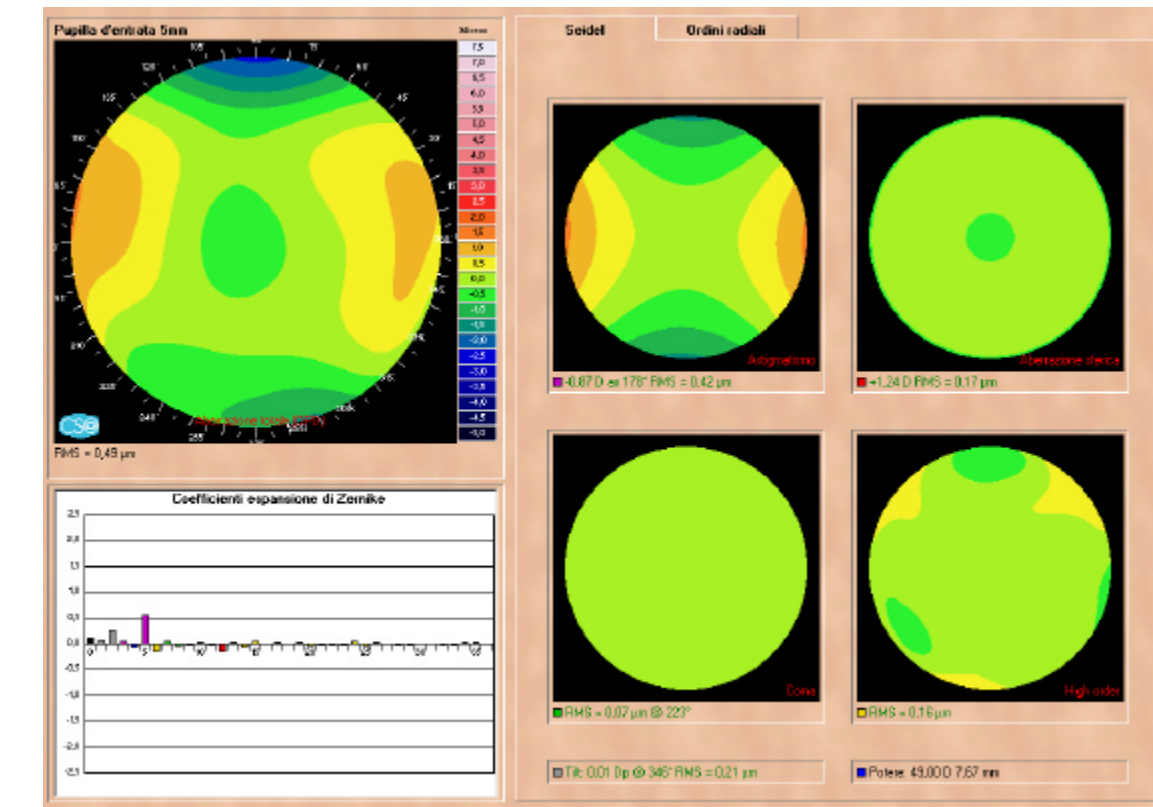


Fig.7 - A sample of pre-treatment corneal wave-front Zernike analysis

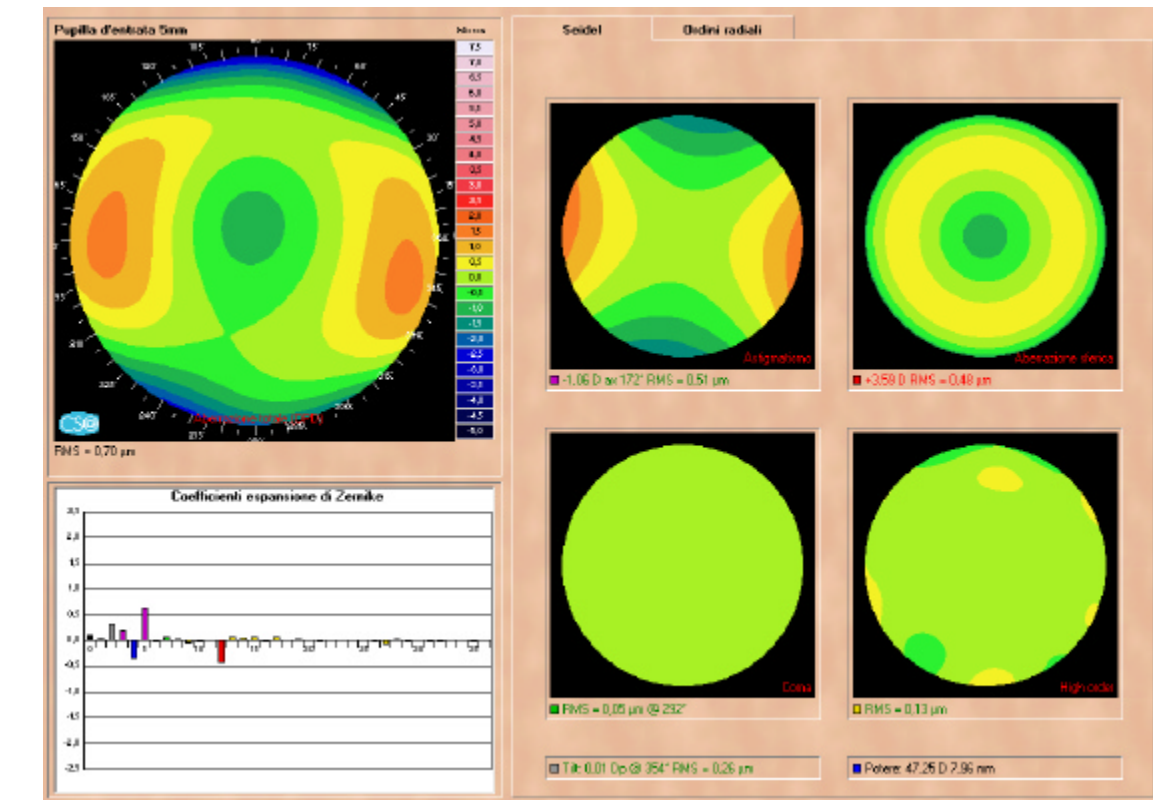


Fig.8 - Post-treatment corneal wave-front Zernike analysis of the same eye shows a significant increase of spherical aberration

CONCLUSIONS

The preliminary results of this study demonstrate that these lenses were effective at producing reduction in myopia and improving unaided vision, with a high predictability of the refractive outcome. The reverse of the asphericity of the cornea increased spherical aberration, that induced some visual symptoms in night vision, but improved the depth of focus. The progressive improvement in subjective quality of vision could involve a sensorial adaptation, that reduced visual symptoms even when aberrations and refraction were stabilized.

Acknowledgements

The author thanks the entire staff of Dr. Ferdinando Romano at the Caserta Civic Hospital (Italy), and Dino Marcuglia for their assistance in the acquisition of data for this study.

Author address:

Antonio Calossi, OD - Via 2 Giugno, 52 - 50052 Certaldo FI, Italy
 Fax: +39 (0)571 656849, e-mail: calossi@tin.it, web: www.ortho-k.it

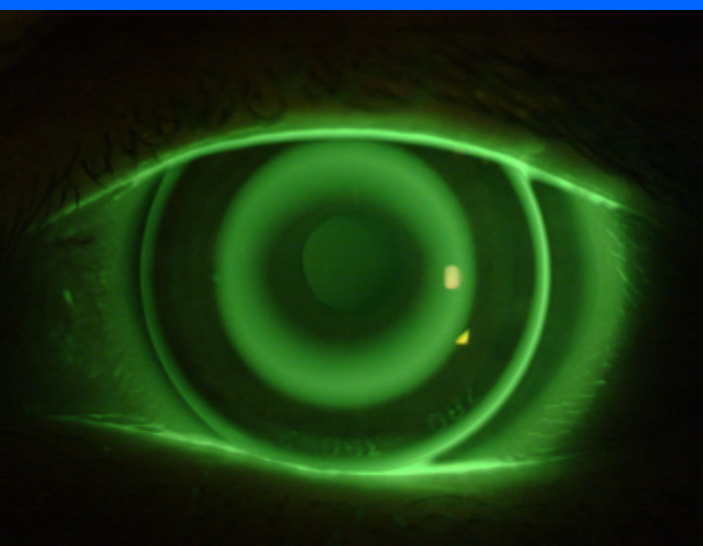


Fig.1 - A sample of optimal fluorescein pattern

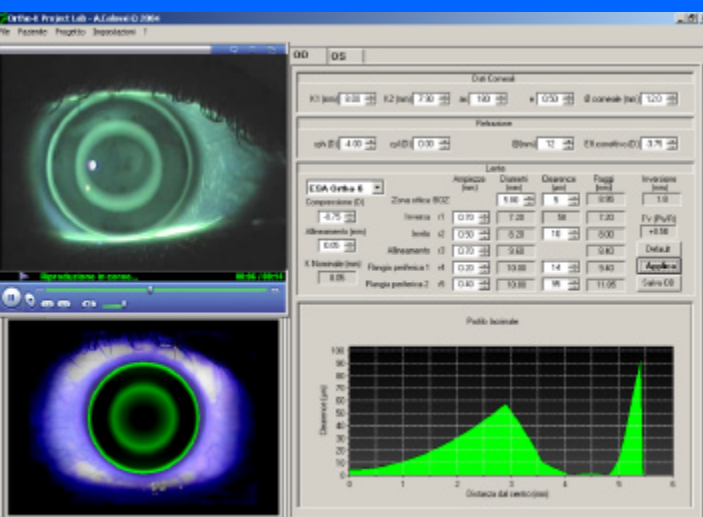


Fig.2 - The software for the customization of the lenses




Fig.3 - Corneal instantaneous curvature after the treatment